

Research Article

Recurrent Lumbar Disc Herniation: One Clinic's Experience

Ezgi Akar,¹ Abdullah Yolcu,¹ Baris Erdogan,¹ Selin Tural Emon,¹ Hakan Somay,¹ Metin Orakdogan,¹ Merih Is²

¹Department of Neurosurgery, Haydarpasa Numune Training and Research Hospital, Istanbul, Turkey

²Department of Neurosurgery, Fatih Sultan Mehmet Training and Research Hospital, Istanbul, Turkey

Abstract

Objectives: The results of surgical treatment for recurrent lumbar disc herniation using repeat microdiscectomy were analyzed. In addition, the recurrence of lumbar disc herniation was evaluated according to age, gender, surgical disc segment, recurrence development time, and the type of modic change observed.

Methods: Between 2012 and 2016, 40 recurrent lumbar disc herniation cases were operated on in the clinic. The patient charts were analyzed retrospectively.

Results: Of the total, 17(42.5%) of the patients were female and 23 (57.5%) were male. The age of the patients ranged from 28 to 71 years (mean: 48±10 years). The interval between primary surgery and the development of recurrent herniation was between 6 and 60 months, with a mean of 19 months (19±16) months. The distribution of the operated level was as follows: 26 (65%) at L4-5, 11 (27.5%) at L5-S1, 2 (5%) at L3-4, and 1 (2.5%) at L2-3. In 85% of the cases (34 patients), there were modic changes in the first surgery.

Conclusion: Recurrent lumbar disc herniation is an important problem in spinal surgery. In this study group, a mean of 48 years of age and modic changes in the primary surgery were observed. At the postoperative 19th month, the probability of recurrence increased. In cases where spinal instability is not detected, successful pain control can only be achieved with repeat microdiscectomy.

Keywords: Recurrent lumbar disc herniation, repeated discectomy, spine

Lumbar disc surgery is the most common surgical procedure in patients with back and leg pain. Although the increased effectiveness of lumbar disc surgery with many new technical and surgical methods, continuation or recurrence of complaints emerges as an important complication of primary surgery. Causes of failure in lumbar disc surgeon can originate from epidural fibrosis, arachnoiditis, foraminal stenosis, and segmental instability.^[1-3] Recurrent disc herniation is defined as disc herniation seen in the same level after a painless period of at least 6 months following the first surgery. Recurrent herniation may be on the same or opposite side.^[4,5] Following primary discectomy, 10-30% of patients continue with back or leg pain, but recurrence rate after microdiscectomy is between 3.5%-10.8% and this rate will increase if postoperative follow-up period is

increased.^[6] Diabetes, obesity, smoking, trauma, male sex, weightlifting, the size of the annular tear, amount of primary discectomy, and end plate degeneration may be associated with recurrence.^[7] The optimal treatment of recurrent disc herniation is still controversial. Some surgeons choose simple discectomy again, while some surgeons advocate fusion surgery. Because recurrent discectomy (ipsilateral/contralateral) requires more disc and posterior spinal component removal (lamina and/or facet joint), recurrent discectomy will increase the likelihood of segmental instability and due to scar tissue; dural tear, and nerve injuries may be greater at simple redisections, some surgeons suggest fusion surgery at first recurrent, regardless of whether instability.^[8]

Address for correspondence: Ezgi Akar, MD. Haydarpasa Numune Egitim ve Arastirma Hastanesi Norosirurji Klinigi, Istanbul, Turkey

Phone: +90 216 386 82 63 **E-mail:** ezgiyacicek@gmail.com

Submitted Date: December 12, 2017 **Accepted Date:** January 10, 2018 **Available Online Date:** January 29, 2018

©Copyright 2018 by Eurasian Journal of Medicine and Investigation - Available online at www.ejmi.org



In our study, we aimed to relate the recurrence of lumbar disc herniation with age, gender, surgical disc distance, recurrence development time and type of modic change. Also we evaluated the surgical treatment results with recurrent lumbar disc herniation by re-microdiscectomy.

Methods

Between 2012 and 2016, 40 recurrent lumbar disc herniation cases (41 surgical interventions) were operated in our clinic. The patients were followed-up and their charts were reviewed in a retrospective manner.

The inclusion criteria for this study were; 1) At least 6 months pain-free period after first surgery, 2) Radicular pain that does not respond to conservative treatment and requires surgery, 3) Ipsilateral herniation at the same level as the first surgery. Preoperative contrasted and non-contrast MRI has done all the patients for differentiation between the scar and the peridural fibrosis. For the evaluation of segmental instability, dynamic X-ray performed to all cases. One of the cases is second recurrent and other cases were first recurrent. 39 cases without instability were treated with re-microdiscectomy, 1 case with instability was treated with re-microdiscectomy and posterolateral stabilization, and 1 case with second recurrent was treated with re-microdiscectomy, posterolateral fusion and TLIF (Fig. 1). Preoperative and postoperative pain (early, the 6th and 12th months) was assessed with visual analog scale (VAS). The patients were evaluated for their age, gender, surgery applied segment, between the first surgery and recurrent interval and preoperative modic changes. Results were statistically evaluated with paired t test and Tukey test. P value was considered significant under the 0.05.

Results

17 (42.5%) of the cases were female and 23 (57.5%) were male. The ages of the cases ranged from 28 to 71 years (mean 48 ± 10). The interval between primary surgery and the development of recurrent herniation was between 6 and 60 months, with a mean of 19 (19 ± 16) months at the most. All of cases had radicular pain and laseque test positivity (Table 1).

The distribution of the operated levels was as follows; 26 at L4-5 (65%), 11 at L5-S1 (27.5%), 2 at L3-4 (5%) and 1 at L2-3 (2.5%) (Table 2). 85% of cases (34 cases), there were modic changes in the first surgery. Preoperative VAS score was detected as 8 ± 0.2 . Postoperative early VAS score was detected as 1 ± 0.2 , and postoperative 6th month 1.5 ± 0.3 , and postop 12 months 2 ± 0.3 . Peroperative dural injury occurred in 1 case (2.5%) and spondylodiscitis in 1 case (2.5%).

Table 1. Patients' clinical manifestations

Clinical Manifestations	Patients (%)
Pain in the foot (with or without back pain)	38 (95)
Motor deficit	29 (72.5)
Sensitivity disorders	22 (55)
Neurogenic claudication	10 (25)
Laseque sign	30 (75)

Disc Level	Frequency	Percent (%)
L4-L5	26	65
L5-S1	11	27.5
L3-L4	2	5
L2-L3	1	2.5

Discussion

In our study, we aim to relate the recurrent of lumbar disc herniation with age, gender, surgical disc segment, recurrence development time and type of modic change.

According to the literature information, 10-30% of patients who underwent lumbar discectomy still complain leg and back pain, but recurrent disc herniation rate is 5-15%.^[9] Most common manifestation of recurrent disc herniation is pain. This pain may be like to preoperative pain or it may be different, and it spreads dermatomal. Motor and sensation deficits, reflex decrease, cauda equina syndrome and neurogenic claudication may be accompanied by pain. Because it manifestation of recurrent disc herniation likes to the other spinal pathologies (lumbar stenosis, segmental instability, peridural fibrosis), differential diagnosis is often difficult.^[9] Lumbosacral x-ray, lumbar intratecal contrasted CT, lumbar CT, myelography and ENMG are used in diagnosis of lumbar disc herniation. Contrast and non-contrast MRI give most information about recurrent disc herniation. MRI also reveals signal changes at the disc segment.^[9, 10]

Lumbar disc herniation is seen in 65-80% in males. In our study, we did not observe any significant difference between the male and female gender. The lumbar disc herniation is more likely (80-90%) seen in the L4-L5 and L5-S1 segments due to their biomechanical effects. We found similar results in our study.

Related factors for lumbar disc herniation are trauma, age, gender, obesity, preoperative minor disc herniation, limited discectomy (versus aggressive), increased range of motion, smoking, occupational lifting, and more preoperative disc degeneration.^[1, 11, 12] Kim et al.^[13] showed a relation between the preoperative modic changes and recurrence. Carrege et al. reported association between the annular competency amount after discectomy, herniation

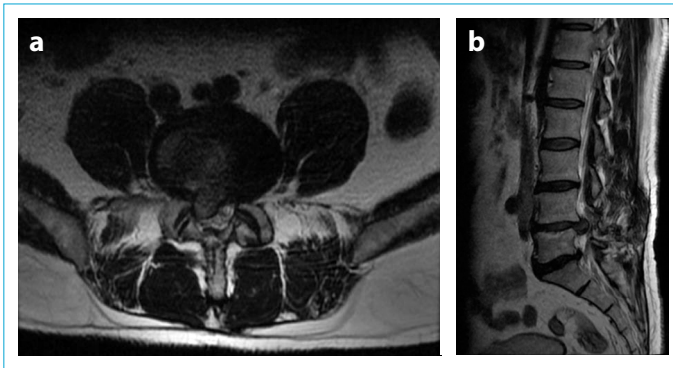


Figure 1. Male, 51 years old, relapsed 2 years after lumbar microdiscectomy for L4-5 right paracentral herniation. (a, b) T2 axial and sagittal MR images showing L4-5 right paracentral herniation and laminectomy defect on the right.

type and recurrence.^[14] Postoperative biomechanical stress on the affected level also caused recurrent lumbar disc herniation.^[13, 14] So, segmental instability should be evaluated before recurrent lumbar disc herniation surgery. Disc degeneration has complex and multifactorial etiologies, and with the age apoptosis increases at the intervertebral disc space.^[15] Barth et al. showed increasing of end plate degeneration and disc dehydration after surgery. At the standard discectomy, anulus incision and nucleus pulposus excision increases disc degeneration.^[16] Kim et al.^[5] showed that decreased intervertebral disc level more stable than normal disc space, and less recurrence seen after primary surgery at this cases.

For treatment of recurrent disc herniation, choosing re-microdiscectomy or re-microdiscectomy with fusion is still controversial. Repeated spinal surgeries are more difficult than primary spinal surgery, because of indistinct anatomical planes and perineural scarring tissue. The risk of segmental instability arises because of more lamina and facet joint tissue will be removed during repetitive discectomies. Because of the possibility of dural tear and nerve injury due to the scar tissue during the surgery, some surgeons suggest fusion surgery, regardless of instability is present.^[8] Fu et al. suggested that re-microdiscectomy with posterolateral fusion in the treatment of recurrent disc herniation more effective in reducing pain than only re-microdiscectomy. Fusion surgery has been associated with more blood loss, more operating time, more complications, and longer hospitalization time.^[17] Complication rate of recurrent disc herniation is about 8-18%. The most common complications are dural tear and infection.^[18] Our complication rate was 5% (1 case of dural tear and 1 case of spondylodiscitis). In our cases, beside the preoperative contrasted and non-contrast MRI, we used lateral dynamic graphs to exclude the presence of instability. We performed only re-mi-

crodiscectomy for our cases that had not have instability. Fusion surgery performed in addition to re-microdiscectomy for 2 cases that we detected instability. We found a significant decrease in postoperative early period, 6th month and 12th month pain levels of our patients. Only re-microdiscectomy complications in our cases were less than literature data.

Conclusion

We observed a mean of 48 year olds, have modic changes and at postoperative nineteenth month patients probability of recurrence was higher. Surgery of recurrent disc herniation is more risky than primary surgery and requires more attention. Therefore, contrasted and non-contrast MRI should be performed for diagnosis and differential diagnosis of medical treatment resistant pain after a painless period of at least 6 months following the first surgery. Recurrent disc herniation detected cases should be confirmed by lateral dynamic graphs for evaluate the instability. If instability is not detected, successful pain control is achieved only by re-microdiscectomy.

Disclosures

Ethics Committee Approval: The study was approved by the Local Ethics Committee.

Peer-review: Externally peer-reviewed.

Conflict of Interest: None declared.

Authorship contributions: Concept – E.A.; Design – E.A., B.E.; Supervision – M.O., M.I.; Materials – A.Y.; Data collection &/or processing – A.Y., E.A.; Analysis and/or interpretation – B.E., S.T.E.; Literature search – E.A., H.S.; Writing – E.A., A.Y.; Critical review – E.A., H.S.

References

1. Dalgic A, Yildirim AE, Okay O, Uckun O, Alagoz F, Polat O, et al. Initial Discectomy Associated with Aging Leading to Adjacent Disc Disease and Recurrence. *Turk Neurosurg* 2016;26:595–600.
2. Loupasis GA, Stamos K, Katonis PG, Sapkas G, Korres DS, Hartofilakidis G. Seven- to 20-year outcome of lumbar discectomy. *Spine (Phila Pa 1976)* 1999;24:2313–7.
3. Swartz KR, Trost GR. Recurrent lumbar disc herniation. *Neurosurg Focus* 2003;15:E10.
4. Sonmez E, Coven I, Sahinturk F, Yilmaz C, Caner H. Unilateral percutaneous pedicle screw instrumentation with minimally invasive TLIF for the treatment of recurrent lumbar disk disease: 2 years follow-up. *Turk Neurosurg* 2013;23:372–8.
5. Kim KT, Park SW, Kim YB. Disc height and segmental motion as risk factors for recurrent lumbar disc herniation. *Spine (Phila Pa 1976)* 2009;34:2674–8.
6. Wang M, Zhou Y, Wang J, Zhang Z, Li C. A 10-year follow-up study on long-term clinical outcomes of lumbar microendoscopic discectomy. *J Neurol Surg A Cent Eur Neurosurg*

- 2012;73:195–8.
7. Stewart G, Sachs BL. Patient outcomes after reoperation on the lumbar spine. *J Bone Joint Surg Am* 1996;78:706–11.
 8. Yoo MW, Hyun SJ, Kim KJ, Jahng TA, Kim HJ. Does obesity make an influence on surgical outcomes following lumbar microdiscectomy? *Korean J Spine* 2014;11:68–73.
 9. Bodiu A. Diagnosis and operatory treatment of the patients with failed back surgery caused by herniated disk relapse. *J Med Life* 2014;7:533–7.
 10. Zagorodny NV, Abakirov MD, Dotsenko VV. Repeated operations for lumbar spine in degenerative diseases. *Politravma* 2008:29–32.
 11. Omidi-Kashani F, Ghayem Hasankhani E, Noroozi HR. Instrumented transforaminal lumbar interbody fusion in surgical treatment of recurrent disc herniation. *Med J Islam Repub Iran* 2014;28:124.
 12. McGirt MJ, Eustacchio S, Varga P, Vilendecic M, Trummer M, Gorenssek M, et al. A prospective cohort study of close interval computed tomography and magnetic resonance imaging after primary lumbar discectomy: factors associated with recurrent disc herniation and disc height loss. *Spine (Phila Pa 1976)* 2009;34:2044–51.
 13. Kim JM, Lee SH, Ahn Y, Yoon DH, Lee CD, Lim ST. Recurrence after successful percutaneous endoscopic lumbar discectomy. *Minim Invasive Neurosurg* 2007;50:82–5.
 14. Carragee EJ, Han MY, Suen PW, Kim D. Clinical outcomes after lumbar discectomy for sciatica: the effects of fragment type and anular competence. *J Bone Joint Surg Am* 2003;85-A:102–8.
 15. Hadjipavlou AG, Tzermiadianos MN, Bogduk N, Zindrick MR. The pathophysiology of disc degeneration: a critical review. *J Bone Joint Surg Br* 2008;90:1261–70.
 16. Barth M, Diepers M, Weiss C, Thomé C. Two-year outcome after lumbar microdiscectomy versus microscopic sequestrectomy: part 2: radiographic evaluation and correlation with clinical outcome. *Spine (Phila Pa 1976)* 2008;33:273–9.
 17. Fu TS, Lai PL, Tsai TT, Niu CC, Chen LH, Chen WJ. Long-term results of disc excision for recurrent lumbar disc herniation with or without posterolateral fusion. *Spine (Phila Pa 1976)* 2005;30:2830–4.
 18. Stolke D, Sollmann WP, Seifert V. Intra- and postoperative complications in lumbar disc surgery. *Spine (Phila Pa 1976)* 1989;14:56–9.